

Implant Cementation: Clinical Problems and Solutions

*Authored by Chandur P. K. Wadhvani, DDS, MSD, and
Alfonso F. Piñeyro, DDS*

Upon successful completion of this CE activity 2 CE credit hours may be awarded

A Peer-Reviewed CE Activity by



DENTISTRY TODAY
is an ADA CERP Recognized Provider

ADA CERP®

Continuing Education Recognition Program

Dentistry Today, Inc. is an ADA CERP Recognized Provider. ADA CERP is a service of the American Dental Association to assist dental professionals in identifying quality providers of continuing dental education. ADA CERP does not approve or endorse individual courses or instructors, nor does it imply acceptance of credit hours by boards of dentistry. Concerns or complaints about a CE provider may be directed to the provider or to ADA CERP at ada.org/goto/cerp.



Approved PACE Program Provider
FAGD/MAGD Credit Approval
does not imply acceptance
by a state or provincial board of
dentistry or AGD endorsement.
June 1, 2009 to May 31, 2012
AGD Pace approval number: 309062

Opinions expressed by CE authors are their own and may not reflect those of *Dentistry Today*. Mention of specific product names does not infer endorsement by *Dentistry Today*. Information contained in CE articles and courses is not a substitute for sound clinical judgment and accepted standards of care. Participants are urged to contact their state dental boards for continuing education requirements.

Implant Cementation: Clinical Problems and Solutions

Effective Date: 01/1/2012 Expiration Date: 01/1/2015

LEARNING OBJECTIVES

After reading this article, the individual will learn:

- Clinical problems that can result from excessive cement when seating implant restorations.
- Clinical solutions for resolving or preventing problems due to excessive cement with implant restorations.

ABOUT THE AUTHORS



Dr. Wadhvani received his specialty certificate in prosthodontics with a master's degree from the University of Washington School of Dentistry. He is currently in private practice in Bellevue and past president of the Washington State Society of Prosthodontics. He is an affiliate instructor at the University of Washington Department of Restorative Dentistry. He has authored several technique and research papers on the subject of implants, and is involved in numerous research projects. He can be reached via e-mail at the address info@nwprosthodontics.com.



Dr. Piñeyro completed his specialty training in prosthodontics at the University of Rochester Eastman Dental Center. He is currently in private practice in Bellevue and is past president of the Washington State Society of Prosthodontics. He is an affiliate instructor at the University of Washington Department of Restorative Dentistry. He has authored several technique and research papers on the subject of implants and is involved in numerous research projects. He can be reached at info@nwprosthodontics.com.

Disclosure: Both authors have received payment for lecturing for Straumann and Nobel Biocare.

INTRODUCTION

Implant cementation as a means of attaching the coronal restoration to the implant fixture has become a routine dental procedure. However, the cementation procedure itself is not without issues (Figures 1a to 1c). Multiple case reports have highlighted problems with excess cement which could ultimately lead to implant failure.¹⁻³ A recent study reported that a direct link between excess cement and peri-implant disease exists.⁴ In this study, the average time before any clinical sign or symptom of peri-implant disease developing was 3 years, with a range of between 4 months and nearly 9.5 years. Little is known about peri-implant disease; it may be multifactorial, with general (patient originated) factors or local factors (at or near the implant site). One theory regarding why there is such a time delay before the problem appears is that the excess cement residue is colonized by bacteria.

This article discusses the clinical importance of avoiding the use of excessive implant cement when restoring implants, including 3 major reasons why an implant restoration is at greater risk from excess cement problems than a natural tooth restoration. Two case reports are presented that demonstrate the problems that can result from excess implant cement, and how these problems were treated.

CASE REPORT NO. 1

A 20-year-old female was referred to a periodontist for implant placement in the area of an existing mandibular right deciduous second molar, the permanent second bicuspid (tooth No. 29) having failed to develop. The site was evaluated for restorative and anatomical needs revealed by a cone beam computed tomography with a radiographic guide *in situ*. An implant (Replace 3.5 mm diameter, 11.5 mm length [Nobel Biocare]) was placed by the periodontist according to the diagnostic criteria derived from the scan. The implant was allowed to heal for a period of 3 months and then was evaluated for both radiographic and clinical integration. The patient returned to her restorative dentist for implant impressions, crown fabrication, and placement of the crown.

Implant Cementation: Clinical Problems and Solutions

Two years postrestoration, the patient re-presented at the periodontist's office with inflammation around the implant site (Figures 1a to 1c). The periodontist removed the crown and abutment, then removed the implant. On inspecting the implant, cement could be seen around the implant body with deposits of calculus on top. The area was surgically debrided and a bioabsorbable collagen wound dressing (CollaPlug [Zimmer Dental]) was sutured across the surgical site. The area was left to heal for 3 months, then a crestal incision was made to retain the attached gingiva and to expose the proposed implant site. The bony defect had filled in, although there was a slight residual buccolingual defect.

A new implant was placed along with a small amount of xenograft mineralized material (Bio-oss [Osteohealth]). The implant site was allowed to heal for 4 months, then the patient was sent to the restoring dentist for placement of a definitive crown, with instructions to use a screw-retained prosthesis.

CASE REPORT NO. 2

A 53-year-old female patient was referred to an implant surgeon with an externally resorbing lesion affecting her maxillary right canine. Although the lesion had been repaired, the patient continued to experience discomfort from this tooth (Figures 2a to 2c). The patient was informed of the treatment options available to her: retain the tooth, undergo endodontic therapy, crown lengthening (to provide enough tooth ferrule), and post/core and crown placement; or extraction of the tooth and replacement with an immediate implant (provided the facial bony plate remained intact at the time of the surgery). The decision to extract and replace with an immediate implant was made by the patient. The tooth was extracted atraumatically, the facial bony plate was confirmed as being intact, and an immediate implant was placed. The critical gap was greater than 2 mm,⁵ so a xenograft bone grafting material (Bio-oss) was placed between the implant and the buccal bone. A temporary abutment was reduced in height, and acrylic was added to form a custom healing abutment. The purpose was to maintain the soft-tissue profile and provide a support frame for the soft tissue to heal against. The patient was provided with an Essix splint for aesthetic purposes only. Five months after the implant was placed, the site was evaluated and the implant was checked for

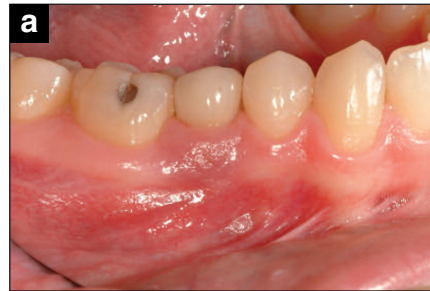

Figure 1a.
Two years after the implant is restored—note the associated enlarged cyanotic gingival tissue.

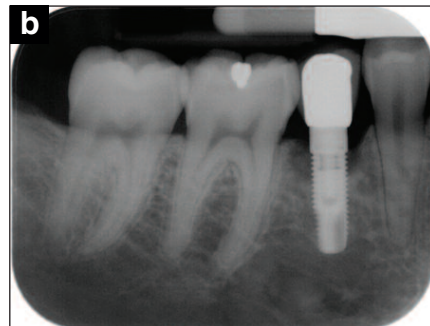


Figure 1b.
Radiograph of the implant site—note the bone loss.



Figure 1c.
The implant is removed. The cement remnants are clearly visible, along with some calculus developing onto the cement.

integration both clinically and radiographically. The patient returned to the restorative dentist for impression-making and implant crown restoration.

The patient returned to the implant surgeon 5 years later complaining of discomfort around the implant and a feeling of “puffiness” (Figures 2d and 2e). The soft tissues appeared inflamed and cyanotic. A decision was made to raise a full-thickness soft-tissue flap and evaluate the implant. The exposed implant showed facial fenestration, with cement residue visible on the implant body. Only a thin bridge of bone existed near the coronal aspect. The cement was removed and the implant was mechanically cleaned using hand instrumentation followed by Air-flow Perio

Implant Cementation: Clinical Problems and Solutions

(EMS), a commercially available amino acid glycine which has been shown to be useful in the removal of bacterial deposits from titanium dental implant surfaces.⁶ A mineral xenograft material (Bio-oss) was placed over the implant, supported by a resorbable collagen membrane. The soft tissues were carefully replaced and sutured.

The patient healed uneventfully and the implant area is currently being monitored every 4 months. No reattachment of bone or improvement in osseointegration is expected; however, it is hoped the soft tissues will remain healthy and closely adapted to the implant body, which is presently stable. Should any adverse effects occur, the implant will be immediately removed and the site surgically debrided, grafted, and a new implant placed.

DISCUSSION

These 2 case reports represent an interesting phenomenon noted with implants: implant disease processes tend to develop either very early—for example, surgical failure—or later on, as with the excess cement issue. Frequently, severe pain is not noticed by the patient, and the gingival tissues may appear slightly inflamed, hiding the problem. This is unlike dentistry involving natural teeth, where problems including pain tend to be more acute and develop early.

Tooth-borne cementation has existed in dentistry for close to 100 years. Excess cement found on tooth-retained restorations with healthy periodontal tissues present few if any problems. This is different for implant-retained restorations, even when the implant has been considered integrated clinically and radiographically.

There are 3 major reasons why an implant restoration is at greater risk from excess cement problems when compared to a natural tooth: biology, tissue depth, and cement types.

1. Biology—The attachment apparatus of the soft tissues is notably different around a tooth when compared to a root form titanium implant⁷ (Figures 3a and 3b). In teeth, the attachment of connective tissue fiber bundles is by means of living tissue in the form of root cementum with horizontal fibers directly inserting into it. These entrapped fibers may become incorporated and mineralized within the cementum layer, resulting in a strong attachment of the healthy soft-tissue complex, which is then held tightly

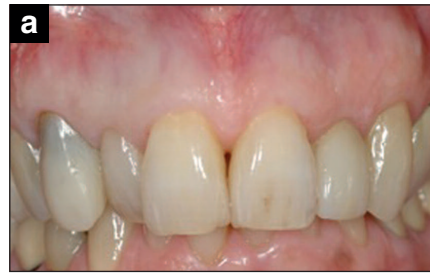

Figure 2a.
Initial presentation: The upper right canine has external resorption defect.

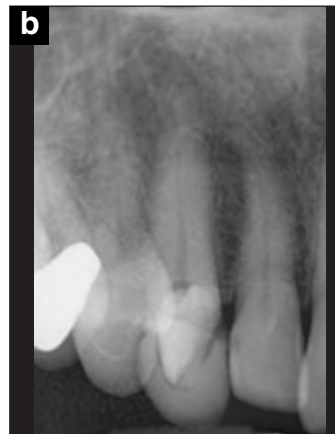

Figure 2b.
Radiograph showing the repaired lesion.

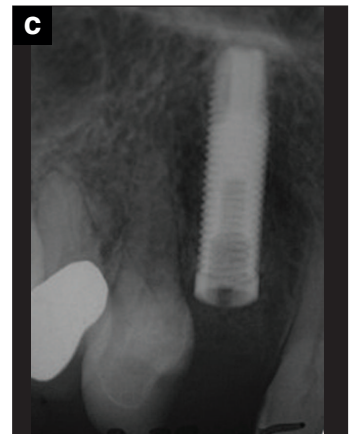

Figure 2c.
Immediate implant placement.

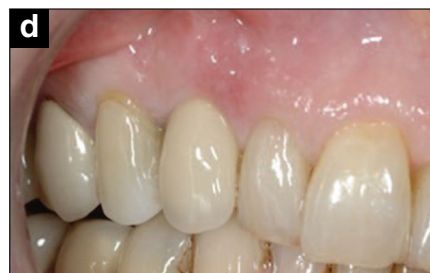

Figure 2d.
Five years postimplant restoration. The tissue adjacent the implant site is inflamed.

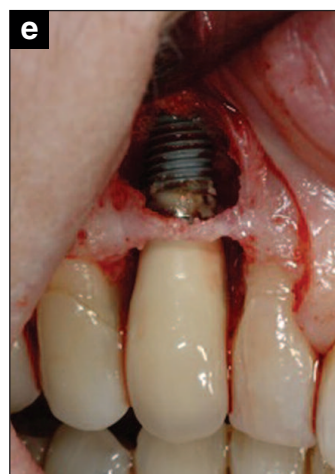

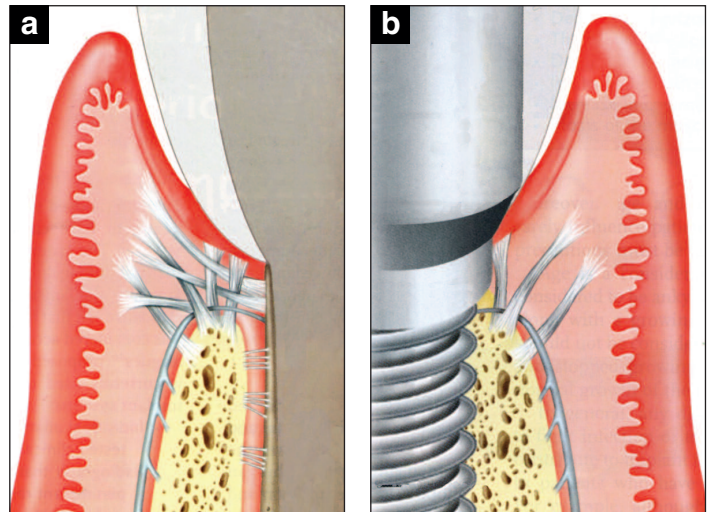
Figure 2e.
Full-thickness flap raised, the bone loss is evident as is the excess cement on the implant body.

Implant Cementation: Clinical Problems and Solutions

against the tooth. In the case of an implant, the connective tissue attachment has fewer fiber bundles, their orientation tends to be parallel and parallel-oblique to the implant long axis, and there is no direct insertion of the fibers into the implant material (there is no cementum). The connective tissue is held in place by a hemidesmosomal adhesion only.

2. Tissue depth—Tooth preparations for cemented restorations commonly have a finish line that is supragingival wherever possible; the only sites that are frequently subgingival are in aesthetic areas. The outline form also follows the tissue height contour as it changes around the tooth, moving higher interproximally where the papillae are. Comparing with implants, the head of an implant is commonly flat and often counter sunk in the anterior region 2 to 4 mm below the level of the mid-buccal gingival tissue to allow for emergence profile contour. Because of the scallop of the gingival tissues, this countersinking can be about 5 to 7 mm from the tip of the papilla to the implant platform at the interproximal area of an anterior tooth.⁸ Increased tissue depths around implants present problems when cleaning excess cement. Raising the cement margins by using custom abutments helps reduce the tissue height issue, but a recent study found that implant crown margins placed any distance subgingivally will result in remnants of excess cement.⁹

3. Cement types—Many forms of cement have been developed for dental use during the last 100 years or more. All have been predominately designed for cementing restorations to teeth, where the principal cause of failure is recurrent dental caries.¹⁰ This disease does not occur in dental implants, which questions the need for the tooth-specific cements. When cementing a crown to a natural tooth, the main challenge relates to the nature of the pulp, dentin, and enamel. Implant abutments are fabricated from a far greater variety of materials. These include titanium alloys, precious metal alloys, alumina, polyaryl-ether-ether-ketone, and zirconia; some of these also present problems with cement retention and adhesion. This has resulted in cement manufacturers designing universal cement materials which have improved adhesive capabilities. This increased retention and bonding strength to the desired abutment material also make cement removal in unwanted areas more difficult or impossible. Studies in the late 1990s reported on the inability



Figures 3a and 3b.

Biological attachment apparatus of a tooth and an implant side-by-side. Note the number, direction and insertion of the connective tissue fibers. (Source: Rose LF, et al. *Prosthodontics. Medicine, Surgery, and Implants*. 2004:613-614.)

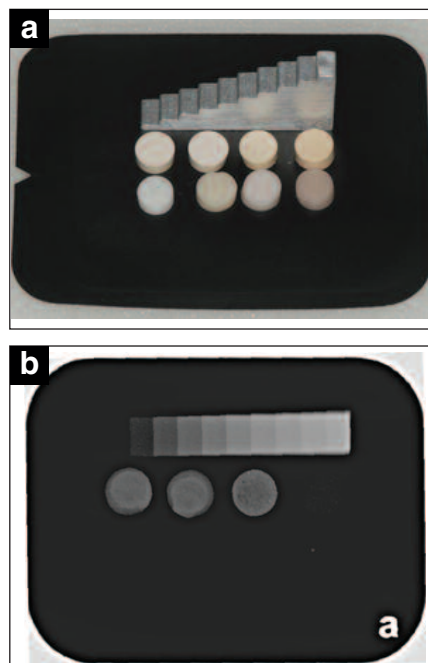


Figure 4a.

Disks of 8 commonly used cements next to a stepped aluminum wedge. Each cement disk is one mm thick.

Figure 4b.

Radiographic results: Three of the 8 disks can be detected. The common feature with these cements is they all contain zinc (TempBond [Kerr], TempBond NE [Kerr], Flecks [Mizzy]).

to clean resin-based materials from implant surfaces¹¹ which at that time were predominantly smooth. With today's rougher surface implants and advances in the adhesive capabilities of cements, this may present even more difficulties.

Many commonly used cements cannot be seen radiographically¹² (Figures 4a and 4b), and to further compound the detection issue, some manufacturers even go

Implant Cementation: Clinical Problems and Solutions

to the extent of making the cements with “aesthetic gingival shading for natural appearance”—these cements are actually pink. This again greatly interferes with the ability of the clinician to find excess cement, since the pink-colored cement easily blends into the surrounding tissues.

Some cements come highly recommended for their retentive capabilities, with literature supporting their use for implants¹³ (eg, Durelon [3M ESPE]). However, when reading the manufacturer’s instructions, it clearly states: “not suitable for cementing titanium.” This again presents issues, as most implants are fabricated from different grades of commercially pure titanium or alloys. When 3M ESPE was contacted, the research department reported that Durelon was found to corrode titanium (e-mail communication, March 2009). This may account for the improved retention when used with titanium implant abutments, but is biologically undesirable as the mobilization of metal ions can be transferred into the tissues and is a known cause of inflammation. Also, should any cement get onto the implant body itself, the corrosion effects would relate directly to the implant body and surrounding tissues.

CLINICAL SOLUTIONS

The ideal properties for a dental cement are often listed as: low viscosity and film thickness, long working time with rapid set at oral temperatures, low solubility, high compressive and tensile strengths, high proportional limit, adhesion to tooth structure and restorative materials, anticariogenic properties, biocompatibility, translucency, and radiopacity.¹⁴ Unfortunately, this list must be tempered by the clinical situation in which the material is being used. For example, a translucent cement may be ideal for an aesthetic restoration on a tooth, but would be inappropriate with an implant restoration. Adhesion to a tooth, with the ability to prevent caries, again may be completely irrelevant when choosing a cement for an implant, where caries is not an issue. If the cement adheres strongly to titanium, especially with a rough surface, there is a risk that peri-implant disease may result. Low viscosity and flow may also affect cemented implant restorations, because frequently soft tissues are purposely displaced by seating an implant crown. When this occurs, the cement can easily be expressed into the more vulnerable soft peri-implant tissues,




Figure 5a. Technique for fabricating a vinyl polysiloxane copy abutment with ideal lute space of 50 μ m—this precoats the inside of the crown, minimizing excess and improving cleanup time.

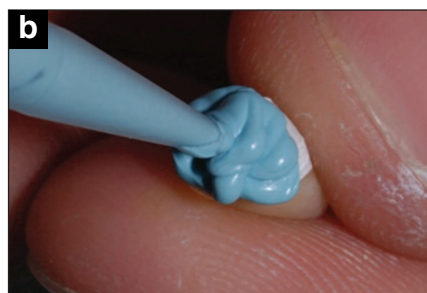

Figure 5b. The inside of the polytetrafluoroethylene crown is filled with a fast setting material (eg, Blu-Mousse [Parkell]).



Figure 5c. When the copy abutment is removed, it is compared to the original abutment, and orientation is noted.

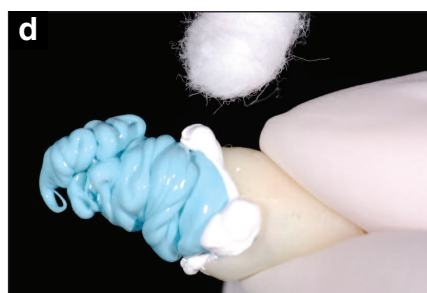

Figure 5d. The crown loaded with cement has the copy abutment seated into it. This allows for the cleanup to be primarily done outside the mouth.

which is unlike a tooth, where the margins tend to be considerably closer to the free gingival margin (or even supragingival), and the attachment mechanism for the soft tissues is much more robust.

No ideal cement exists in dentistry, which explains the large selection of different materials available. The implant restoring dentist should also be aware that cements more suited to traditional tooth form dentistry may not be suitable for use with implants. In the early years of cemented implant

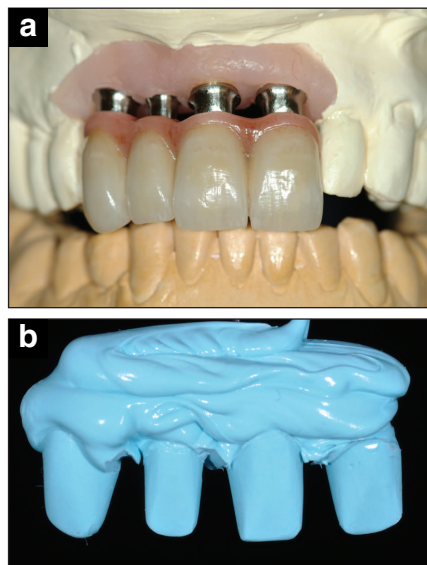
Implant Cementation: Clinical Problems and Solutions

restorations, much was made of temporary versus permanent cementation, with advocates for each technique. The main factor for considering retention as the driving force for cement selection was due to concerns with abutment screw loosening. This was a result of a lack of understanding of the mechanisms of screw fasteners, which under ideal conditions (using appropriate torque values) can actually enhance a joint, clamping components together and preventing loosening effects. A systematic review¹⁵ of the incidence of screw loosening in single implant restorations actually concluded that abutment screw loosening is a rare event in single-implant restorations regardless of the geometry of implant-abutment connection, provided that proper antirotational features and torque are employed.

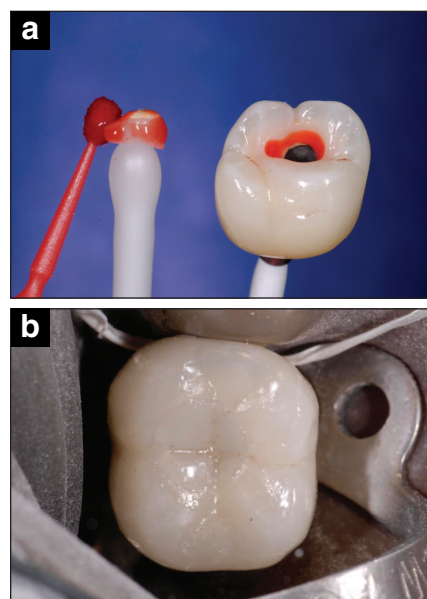
It is the authors' opinion that, as with tooth form dentistry, in most cases the restoration should be cemented permanently, with the retention properties of the cementing media tempered against other factors, such as ability to remove excess cement, color, biocompatibility, non-destructive to materials, radiopacity, and other factors.

The desire to develop implant restoration emergence profiles via restorative procedures that mimic the natural dentition also impacts the health of the peri-implant tissue, and is a topic that is beyond the scope of this article. For the reasons stated above, it is clear that any implant cement in excess may pose a clinical problem. One means of reducing the problem is controlling cement excess by reducing the amount of cement used in the first instance. Several techniques have been described in the literature whereby excess cement is extruded prior to cementation.^{16,17} Some of these use the implant system's manufactured "copy" abutment, which may not completely fulfill the function of precoating the inside of the restoration, as many copy abutments are in fact larger than the actual abutment that is used intraorally. Therefore, the coating will be insufficient to fill the cement space.

An improved method is to fabricate a copy abutment out of a fast-setting vinyl polysiloxane (VPS) material (eg, Blu-Mousse [Parkell]) using a liner material such as polytetrafluoroethylene (PTFE), which is readily available at most hardware stores and sold as "plumbers' tape." The PTFE is easily sterilized by cutting into short strips 6 inches long, placing in a sterilization pouch, and autoclaving. The



Figures 6a and 6b. Multiunit copy abutments to be used for cementing a 4-unit prosthesis.



Figures 7a and 7b. Examples of the implant crown with an adhesive plug:
(a) The screw-retained implant crown has a plug fabricated from the same pressed porcelain. It is etched, silanated, and ready to be bonded into the screw access hole.
(b) Providing excellent aesthetics as well as giving complete control of the occlusion.

PTFE is cut into a half-inch strip (Figures 5a to 5d) then adapted to the inside of the crown. To help the tape adapt, precoat the crown with KY Jelly (Johnson & Johnson) or other water-soluble lubricant, which is washed out after the custom copy abutment is made. This spacer will provide a luting space of 50 μ m (approximately the ideal thickness for cement space) such that the copy abutment fabricated is 50 μ m smaller than the crown itself. The spacer is removed when the VPS copy abutment material is set. The crown may then be loaded with cement arbitrarily, so that when

Implant Cementation: Clinical Problems and Solutions

the copy abutment is inserted into the crown, as it is seated completely, excess is extruded. All of this is accomplished extraorally. The crown intaglio is then checked for voids (a little extra cement may be used if required) and the precoated crown is inserted with close to the ideal amount of cement (Figures 5a to 5d). The added advantage of rapid cleanup is also of clinical benefit. This technique can also be used on multiple abutments, eg, a bridge (Figures 6a and 6b), and is not limited to the use of implants alone; it can also be used for natural teeth.

Another means of solving the excess cement problem is to consider screw-retained restorations; for example, the implant crown with an adhesive plug (ICAP) (Figures 7a and 7b). Screw-retained crowns are considered by some as being problematic with regard to aesthetics and control of the occlusion; however, the ICAP restoration has overcome both of these complaints. The ICAP¹⁸ is a simple means of

closing a screw access hole rapidly and easily, which also eliminates all cement subgingivally. A pressed porcelain plug is made which is similar to an inlay, and the porcelain can be etched with hydrofluoric acid, silanated, and cemented into the screw access hole. With the advent of pressed ceramic systems, the ability to control aesthetics and occlusion is possible.

CONCLUSION

The use of inappropriate or excessive amounts of cement when placing implant restorations can result in clinical complications. With judicious material selection (including following the manufacturer's instructions), careful prosthetic management of margin height, and using techniques that help reduce cement extrusion (possibly even converting to screw retention), the clinician may reduce or even eliminate these cement related issues.

Implant Cementation: Clinical Problems and Solutions

REFERENCES

1. Pauletto N, Lahiffe BJ, Walton JN. Complications associated with excess cement around crowns on osseointegrated implants: a clinical report. *Int J Oral Maxillofac Implants*. 1999;14:865-868.
2. Gapski R, Neugeboren N, Pomeranz AZ, et al. Endosseous implant failure influenced by crown cementation: a clinical case report. *Int J Oral Maxillofac Implants*. 2008;23:943-946.
3. Callan DP, Cobb CM. Excess cement and peri-implant disease. *Journal of Implant & Advanced Clinical Dentistry*. 2009;1:61-68.
4. Wilson TG Jr. The positive relationship between excess cement and peri-implant disease: a prospective clinical endoscopic study. *J Periodontol*. 2009;80:1388-1392.
5. Chen ST, Wilson TG Jr, Hämmerle CH. Immediate or early placement of implants following tooth extraction: review of biologic basis, clinical procedures, and outcomes. *Int J Oral Maxillofac Implants*. 2004;19(suppl):12-25.
6. Schwarz F, Ferrari D, Popovski K, et al. Influence of different air-abrasive powders on cell viability at biologically contaminated titanium dental implants surfaces. *J Biomed Mater Res B Appl Biomater*. 2009;88:83-91.
7. Rose LF, Mealey BL, Genco RJ, et al. *Periodontics: Medicine, Surgery, and Implants*. St. Louis, MO: Mosby; 2004:613-614.
8. Sadan A, Blatz MB, Bellerino M, et al. Prosthetic design considerations for anterior single-implant restorations. *J Esthet Restor Dent*. 2004;16:165-175.
9. Linkevicius T, Vindasiute E, Puisys A, et al. The influence of margin location on the amount of undetected cement excess after delivery of cement-retained implant restorations. *Clin Oral Implants Res*. 2011;22:1379-1384.
10. Goodacre CJ, Bernal G, Rungcharassaeng K, et al. Clinical complications in fixed prosthodontics. *J Prosthet Dent*. 2003;90:31-41.
11. Agar JR, Cameron SM, Hughbanks JC, et al. Cement removal from restorations luted to titanium abutments with simulated subgingival margins. *J Prosthet Dent*. 1997;78:43-47.
12. Wadhvani C, Hess T, Faber T, et al. A descriptive study of the radiographic density of implant restorative cements. *J Prosthet Dent*. 2010;103:295-302.
13. Mansour A, Ercoli C, Graser G, et al. Comparative evaluation of casting retention using the ITI solid abutment with six cements. *Clin Oral Implants Res*. 2002;13:343-348.
14. Air Force Medical Service Web site. Dental Luting Cements. http://airforcemedicine.afms.mil/-idc/groups/public/documents/afms/ctb_108338.pdf. Accessed December 8, 2011.
15. Theoharidou A, Petridis HP, Tzannas K, et al. Abutment screw loosening in single-implant restorations: a systematic review. *Int J Oral Maxillofac Implants*. 2008;23:681-690.
16. Dumbrigue HB, Abanomi AA, Cheng LL. Techniques to minimize excess luting agent in cement-retained implant restorations. *J Prosthet Dent*. 2002;87:112-114.
17. Wadhvani C, Piñeyro A. Technique for controlling the cement for an implant crown. *J Prosthet Dent*. 2009;102:57-58.
18. Wadhvani C, Piñeyro A, Avots J. An esthetic solution to the screw-retained implant restoration: introduction to the implant crown adhesive plug: clinical report. *J Esthet Restor Dent*. 2011;23:138-143.

Implant Cementation: Clinical Problems and Solutions

POST EXAMINATION INFORMATION

To receive continuing education credit for participation in this educational activity you must complete the program post examination and receive a score of 70% or better.

Traditional Completion Option:

You may fax or mail your answers with payment to *Dentistry Today* (see Traditional Completion Information on following page). All information requested must be provided in order to process the program for credit. Be sure to complete your "Payment," "Personal Certification Information," "Answers," and "Evaluation" forms. Your exam will be graded within 72 hours of receipt. Upon successful completion of the post-exam (70% or higher), a letter of completion will be mailed to the address provided.

Online Completion Option:

Use this page to review the questions and mark your answers. Return to **dentalcetoday.com** and sign in. If you have not previously purchased the program, select it from the "Online Courses" listing and complete the online purchase process. Once purchased the program will be added to your **User History** page where a **Take Exam** link will be provided directly across from the program title. Select the **Take Exam** link, complete all the program questions and **Submit** your answers. An immediate grade report will be provided. Upon receiving a passing grade, complete the online evaluation form. Upon submitting the form, your **Letter Of Completion** will be provided immediately for printing.

General Program Information:

Online users may log in to **dentalcetoday.com** any time in the future to access previously purchased programs and view or print letters of completion and results.

POST EXAMINATION QUESTIONS

1. **Peri-implant disease has been positively linked to:**
 - a. Implant type.
 - b. Connection type.
 - c. Excess luting cement.
 - d. Implant location.
2. **On average, how long does it take for the peri-implant disease to demonstrate signs and symptoms after the cementation of an implant crown?**
 - a. One week.
 - b. Three weeks.
 - c. Three months.
 - d. Three years.
3. **The cause of cement induced peri-implant disease is considered to be a result of:**
 - a. Cement breakdown.
 - b. Bacterial colonization of excess cement.
 - c. Lack of oral hygiene.
 - d. Toxic effects of cements.
4. **When an implant is placed 2 to 4 mm deep to the facial gingiva, and a papilla is present proximally, how deep is the implant head at the papilla site commonly?**
 - a. Two to 3 mm.
 - b. Three to 4 mm.
 - c. Four to 5 mm.
 - d. Five to 7 mm.
5. **The soft-tissue connective tissue attachment around an implant has the following feature:**
 - a. Sharpey fibers directly inserted into the titanium.
 - b. Is identical to a tooth attachment.
 - c. Is hemidesmosomal.
 - d. Always has horizontal fibers inserting into the implant.
6. **The most appropriate color for an implant cement is:**
 - a. The same as the soft tissues so it blends in easily.
 - b. Clear or transparent so any excess will not compromise the aesthetic result of the restoration.
 - c. Gingival shaded.
 - d. A good contrast to the surrounding tissues so it can be easily detected and removed.
7. **Durelon polycarboxylate cement is:**
 - a. Recommended for titanium structures due to its color.
 - b. Not recommended for titanium structures due to possible corrosion—manufacturer's instructions.
 - c. Not recommended for its radiopacity.
 - d. Not recommended due to retentive properties.

Implant Cementation: Clinical Problems and Solutions

8. Implant cements that are highly adhesive:

- a. Are difficult to remove from implant surfaces and may cause a problem if in excess.
- b. Should always be used for increased retention.
- c. Are easy to clean if excess cement exists.
- d. Are easy to detect on radiographs.

9. Cementing restorations onto implant abutments:

- a. Is the same as cementing crowns onto teeth.
- b. Requires greater care than traditional tooth cementation procedures.
- c. Is never a problem.
- d. Should use the same cements as with teeth.

10. Implants can fail due to:

- a. Excess cement.
- b. Patient selection.
- c. Poor surgical technique.
- d. All of the above.

11. An ideal implant cement should:

- a. Allow easy removal of any excess, be easily visible, radiopaque, not affect materials negatively.
- b. Difficult to remove from titanium surfaces for ideal retention.
- c. Colored so it blends in with the soft tissues.
- d. Translucent and radiolucent.

12. Teflon tape, polytetrafluoroethylene (plumbers' tape):

- a. Is readily available, inexpensive, sterilizable, and is about 50 μm thick.
- b. Is expensive, difficult to find.
- c. Is left inside the crown during cementation.
- d. Is 200 μm thick.

13. A way to avoid excess cement issues is to:

- a. Use a cement that corrodes titanium.
- b. Use a colored cement.
- c. Use a cement that is most retentive.
- d. Control the amount of cement used within the crown.

14. What negative effect will corrosion of titanium have on the soft tissues?

- a. It produces an unaesthetic appearance.
- b. It mobilizes ions which are a known cause of inflammation.
- c. It discolors the tissue.
- d. It causes an increase in papilla height.

15. A recent study on the depth of implant crown margins regarding depth of subgingival placement and excess cement removal concluded:

- a. The deeper subgingival placement resulted in less excess cement.
- b. Excess cement was only detected in the deep subgingival margins.
- c. All margins resulted in excess cement remnants; the deeper margins were more problematic.
- d. It doesn't matter how deep the margin is placed; excess cement is easily removed.

16. When selecting an implant cement:

- a. Choose the most retentive.
- b. Choose the most aesthetic.
- c. Choose one that is easily seen, easy to remove when in excess, radiopaque, and does not corrode.
- d. Choose one that is specifically designed for implants.

Implant Cementation: Clinical Problems and Solutions

PROGRAM COMPLETION INFORMATION

If you wish to purchase and complete this activity traditionally (mail or fax) rather than online, you must provide the information requested below. Please be sure to select your answers carefully and complete the evaluation information. To receive credit you must answer at least 12 of the 16 questions correctly.

Complete online at: dentalcetoday.com

TRADITIONAL COMPLETION INFORMATION:

Mail or fax this completed form with payment to:

Dentistry Today
Department of Continuing Education
100 Passaic Avenue
Fairfield, NJ 07004
Fax: 973-882-3622

PAYMENT & CREDIT INFORMATION:

Examination Fee: \$40.00 **Credit Hours:** 2.0

Note: There is a \$10 surcharge to process a check drawn on any bank other than a US bank. Should you have additional questions, please contact us at (973) 882-4700.

- ☐ I have enclosed a check or money order.
☐ I am using a credit card.

My Credit Card information is provided below.

- ☐ American Express ☐ Visa ☐ MC ☐ Discover

Please provide the following (please print clearly):

Exact Name on Credit Card

Credit Card #

Expiration Date

Signature



Approved PACE Program Provider
FAGD/MAGD Credit Approval
does not imply acceptance
by a state or provincial board of
dentistry or AGD endorsement.
June 1, 2009 to May 31, 2012
AGD Pace approval number: 309062

ADA CERP®
Continuing Education Recognition Program
Dentistry Today, Inc. is an ADA CERP Recognized
Provider. ADA CERP is a service of the American
Dental Association to assist dental professionals in
identifying quality providers of continuing dental
education. ADA CERP does not approve or endorse
individual courses or instructors, nor does it imply
acceptance of credit hours by boards of dentistry.
Concerns or complaints about a CE provider may be
directed to the provider or to ADA CERP at
ada.org/goto/cerp.

PERSONAL CERTIFICATION INFORMATION:

Last Name (PLEASE PRINT CLEARLY OR TYPE)

First Name

Profession / Credentials

License Number

Street Address

Suite or Apartment Number

City

State

Zip Code

Daytime Telephone Number With Area Code

Fax Number With Area Code

E-mail Address

ANSWER FORM: COURSE #: 145

Please check the correct box for each question below.

- | | |
|--|---|
| 1. <input type="checkbox"/> a <input type="checkbox"/> b <input type="checkbox"/> c <input type="checkbox"/> d | 9. <input type="checkbox"/> a <input type="checkbox"/> b <input type="checkbox"/> c <input type="checkbox"/> d |
| 2. <input type="checkbox"/> a <input type="checkbox"/> b <input type="checkbox"/> c <input type="checkbox"/> d | 10. <input type="checkbox"/> a <input type="checkbox"/> b <input type="checkbox"/> c <input type="checkbox"/> d |
| 3. <input type="checkbox"/> a <input type="checkbox"/> b <input type="checkbox"/> c <input type="checkbox"/> d | 11. <input type="checkbox"/> a <input type="checkbox"/> b <input type="checkbox"/> c <input type="checkbox"/> d |
| 4. <input type="checkbox"/> a <input type="checkbox"/> b <input type="checkbox"/> c <input type="checkbox"/> d | 12. <input type="checkbox"/> a <input type="checkbox"/> b <input type="checkbox"/> c <input type="checkbox"/> d |
| 5. <input type="checkbox"/> a <input type="checkbox"/> b <input type="checkbox"/> c <input type="checkbox"/> d | 13. <input type="checkbox"/> a <input type="checkbox"/> b <input type="checkbox"/> c <input type="checkbox"/> d |
| 6. <input type="checkbox"/> a <input type="checkbox"/> b <input type="checkbox"/> c <input type="checkbox"/> d | 14. <input type="checkbox"/> a <input type="checkbox"/> b <input type="checkbox"/> c <input type="checkbox"/> d |
| 7. <input type="checkbox"/> a <input type="checkbox"/> b <input type="checkbox"/> c <input type="checkbox"/> d | 15. <input type="checkbox"/> a <input type="checkbox"/> b <input type="checkbox"/> c <input type="checkbox"/> d |
| 8. <input type="checkbox"/> a <input type="checkbox"/> b <input type="checkbox"/> c <input type="checkbox"/> d | 16. <input type="checkbox"/> a <input type="checkbox"/> b <input type="checkbox"/> c <input type="checkbox"/> d |

PROGRAM EVALUATION FORM

Please complete the following activity evaluation questions.

Rating Scale: Excellent = 5 and Poor = 0

Course objectives were achieved.

Content was useful and benefited your clinical practice.

Review questions were clear and relevant to the editorial.

Illustrations and photographs were clear and relevant.

Written presentation was informative and concise.

How much time did you spend reading the activity and completing the test?